

Gonioscopy-assisted Transluminal Trabeculotomy (GATT): Thermal Suture Modification With a Dye-stained Rounded Tip

Davinder S. Grover, MD, MPH and Ronald L. Fellman, MD

Purpose: To describe a novel technique for thermally marking the tip of a suture, in preparation for a gonioscopy-assisted transluminal trabeculotomy.

Patient: One patient was used as an example for this technique.

Methods: Technique report.

Results and Conclusions: The authors introduce a modification of a novel surgical procedure (GATT) in which a suture is marked and thermally blunted allowing a proper visualization while performing an ab interno, minimally invasive, circumferential 360-degree suture trabeculotomy. The authors have previously reported on the GATT surgery with the use of an illuminated microcatheter, which allowed for visualization of the tip of the catheter as it circumnavigated Schlemm canal. This modification allows for similar visualization of the tip of the suture, however, is much more cost-effective while still maintaining similar safety.

Key Words: trabeculotomy, minimally invasive glaucoma surgery (MIGS), ab interno, GATT, gonioscopy-assisted transluminal trabeculotomy

(*J Glaucoma* 2016;25:501–504)

Circumferential 360-degree suture trabeculotomy is a well-established surgical technique for the treatment of primary and secondary open-angle glaucomas.^{1–8} Traditionally, performed via an ab externo approach with a 6-0 polypropylene suture, various types of nylon sutures have also been used.^{2,6,9} More recently, authors have reported using an illuminated microcatheter (iTrack, Ellex) to accomplish this same surgery.^{10,11} A benefit of the illuminated microcatheter is the ability to visualize the blinking tip of the catheter as it circumnavigates the Schlemm canal. This allows the surgeon to locate the catheter at all times and recognize immediately if it deviates into the suprachoroidal space. Moreover, if the catheter stops in the canal or goes down a collector channel, the surgeon can recognize the location and can perform a cut-down at that site or apply pressure at various locations to ensure the catheter stays in the Schlemm canal.

Received for publication October 30, 2014; accepted August 16, 2015. From the Glaucoma Associates of Texas, Dallas, TX.

Disclosure: The authors declare no conflict of interest.

Reprints: Davinder S. Grover, MD, MPH, Glaucoma Associates of Texas, 10740 N. Central Expressway, Suite 300, Dallas, TX 75231 (e-mail: dgrover@glaucomaassociates.com).

Supplemental Digital Content is available for this article. Direct URL citations appear in the printed text and are provided in the HTML and PDF versions of this article on the journal's Website, www.glaucomajournal.com.

Copyright © 2015 Wolters Kluwer Health, Inc. All rights reserved.

DOI: 10.1097/IJG.0000000000000325

Grover et al³ reported on the preliminary results of a novel technique for performing an ab interno circumferential trabeculotomy termed gonioscopy-assisted transluminal trabeculotomy (GATT). In that initial study, the vast majority of the surgeries were performed using an illuminated microcatheter (iTrack; Ellex, California) with a small portion (5% to 10%) being performed with a suture. This initial study found no statistically significant difference between outcomes with the suture and outcomes with the microcatheter. One of the concerns with the microcatheter is the cost. The authors now report on a modified technique in which a marked 4-0 clear nylon suture is used to perform the same technique. When performing an ab interno or ab externo trabeculotomy with a suture, it is occasionally difficult to visualize the tip of the suture with a gonioscopy intraoperatively, especially with a clear suture. However, with this novel technique, the surgeon is now able to visualize the tip of the clear suture relatively easily as it circumnavigates the canal. Occasionally, one is even able to visualize the marked suture tip externally through the sclera without the aid of a gonioscopy. Various sutures can be used including 4-0 or 5-0 clear or black nylon. Some surgeons have successfully completed this technique with a prolene suture, however, the authors find prolene to be very rigid with a greater potential for damaging the intraocular structures. The authors prefer the clear nylon as the distal tip is easier to visualize. When the authors have used the black nylon, occasionally the suture blends in with the darkly pigmented trabecular meshwork (TM) and blood and is more difficult to visualize. The clear nylon stretches the TM and pushes blood to the side, creating a clearer appearing TM once the canal is cannulated by the clear nylon suture.

To the authors' knowledge, this is the first time this novel method for marking a clear suture has been reported. Using the marked suture increases the visualization (and ease) with which a suture can be used to perform GATT and is much more cost-effective than the microcatheter.

SURGICAL PROCEDURE

The authors have previously reported the detailed steps of the GATT procedure, therefore a brief summary of the key steps are described below. More attention will be placed on the novel marking technique.

A 4-0 nylon suture clear monofilament (Ethilon; Ethicon, Cincinnati, OH) is cut to the appropriate length so that it is sufficiently long to pass around the Schlemm canal. The tip of the suture is blunted with a heating source. The authors use a low-temperature cautery with an ophthalmic fine tip (Bovie Medical Corporation, FL). The tip of the suture should be rounded with a rectangular appearance (Fig. 1). Chin et al⁶ reported on the appearance of a nylon

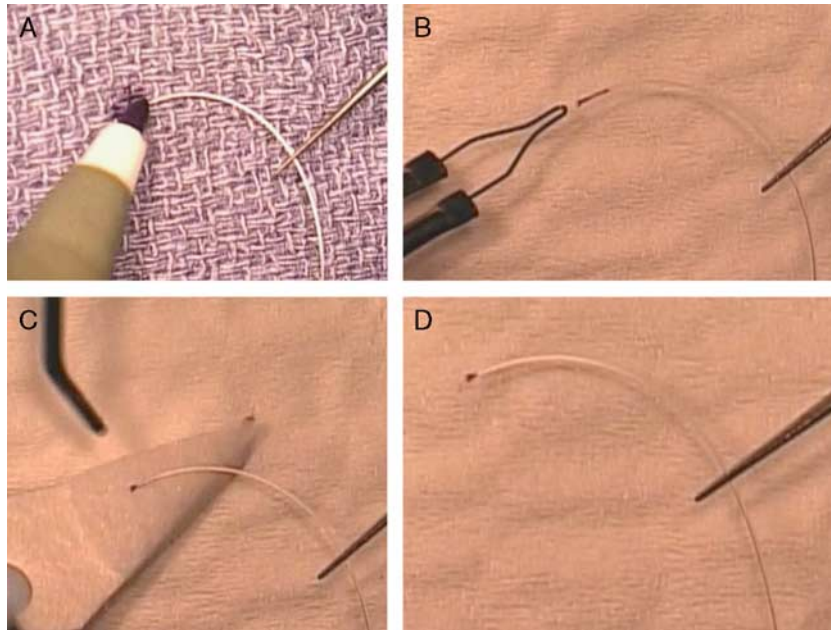


FIGURE 1. Photograph demonstrating the marking of a clear 4.0 nylon suture. A, The tip of the suture is first marked with a surgical marking pen. B, A low-temperature ophthalmic cautery is used to blunt the tip. This melts the tip of the suture and incorporates the ink into the suture. C, Balanced salt solution and a weck-cell sponge is used to remove the remaining ink from the tip. D, The final picture of a blunted 4.0 nylon suture with a permanently marked tip.

suture following blunting with a thermal cautery device. Before heating the tip, an ophthalmic surgical marking pen is used to mark the tip. The ink is then melted into the blunted tip of the catheter and becomes permanently integrated, allowing for visualization of the colored tip (Fig. 1).

After a standard sterile preparation, the surgical eye is draped and an open wire nasal lid speculum inserted to hold the eyelids open. A 23-G needle paracentesis track is placed in either the superonasal or inferonasal quadrant. This initial track serves as the entry site for the marked suture. A viscoelastic (sodium hyaluronate) is injected into the anterior chamber through this site. A temporal paracentesis is created. A suture (the authors prefer a 4-0 nylon, however, others prefer a 6-0 polypropylene suture) with a blunted tip is inserted into the anterior chamber through the entry site with the tip resting in the nasal angle. The microscope and the patient's head are then oriented to allow proper visualization of the nasal angle with a Swan-Jacob gonioscopes. A 1 to 2 mm goniotomy is created in the nasal angle with a microsurgical blade through the temporal site (Fig. 2A). Microsurgical forceps are then introduced through the temporal site and used to grasp the marked suture within the anterior chamber. The distal tip of the suture is then inserted into the Schlemm canal at the goniotomy incision (Fig. 2B). Within the anterior chamber, the microsurgical forceps are used to advance the suture in a counter-clockwise direction through the canal circumferentially 360 degrees (Fig. 2C).

The progress of the suture can be appreciated through use of a gonioscopic prism. Previously, finding the tip of the suture was more challenging because it was not marked and difficult to visualize. Marking the tip has greatly increased the ease with which a suture can be used for a GATT surgery (Fig. 3). Frequently, as in this case, the suture can be visualized externally (Fig. 2D). In this patient, as sometimes

occurs, the suture stopped in the inferonasal quadrant. This required cutting down over the suture ab internally and retrieving the distal end, thereby creating a 270-degree trabeculotomy (Figs. 2E-I). The suture was then passed, through a new paracentesis, in a clockwise direction to treat the remaining 90 degrees of the TM (Figs. 2J-L). The viscoelastic is then removed from the anterior chamber by a bimanual irrigation-aspiration system to wash the anterior chamber of blood. Near the end of the procedure, a 25% anterior chamber fill with viscoelastic can be instilled to help tamponade bleeding from the canal postoperatively. Postoperative corticosteroid (subconjunctival or intracameral) and antibiotic drops are given per the surgeon's discretion. The surgical video (video, Supplemental Digital Content 1, <http://links.lww.com/IJG/A69>) also demonstrates the key portions of the procedure.

In the vast majority of cases with the catheter, it is passed 360 degrees without obstruction. Although the suture is usually passed 360 degrees in 1 direction and the distal end is retrieved after having circumnavigated the entire canal, the authors feel it is more likely than the catheter to stop after 270 degrees. As such, the authors included an example in which the suture has stopped, to illustrate a solution to this problem.

REPRESENTATIVE CASE

A 42-year old man of Indian decent presented for glaucoma evaluation of his right eye. He had no significant past medical history, and his past ocular history was significant for laser-assisted in situ keratomileusis (LASIK) in both eyes (OU) 10 years ago, high myopia OU, and a retinal detachment in his right eye (OD) that was repaired with laser retinopexy. He subsequently developed elevated intraocular pressure (IOP) with presumed Schwartz syndrome OD.




FIGURE 2. Intraoperative photographs demonstrating a gonioscopy-assisted transluminal trabeculotomy procedure with a 4.0 nylon suture. Throughout the images, for better orientation, “N” represents the nasal limbus and “T” represents the temporal limbus. A, A goniotomy is created with a microsurgical blade. B, Microsurgical forceps are used to cannulate the Schlemm canal through the goniotomy site. C, The marked 4.0 nylon suture is being passed through the canal. D, The suture has stopped having been passed 270 degrees around the canal. The white arrow points to the tip of the marked suture. E, One can appreciate the marked suture tip with the aid of a gonioprism. F, A goniotomy is performed through the trabecular meshwork overlying the marked suture tip. G, The suture is retrieved through the goniotomy site. H, Traction is placed on the distal and proximal portion of the suture. I, A 270-degree goniotomy is performed. The black arrow represents the site of the first goniotomy (nasal). The red arrow represents the site of the second goniotomy (inferotemporal). The red arrow represents the area where a trabeculotomy is being created. J, The suture is then passed in the clockwise direction, through a new paracentesis, in an effort to treat the remaining 90 degrees. K, The suture has been passed 360 degrees around the canal and the distal end has been retrieved. L, Traction is placed on the proximal and distal end of the suture, thus treating the remaining 90 degrees and completing the entire 360-degree trabeculotomy.

Upon presentation, his vision was 20/20 OU. His IOP OD was 27 mm Hg on combined timolol/brimonidine ophthalmic solution, dorzolamide ophthalmic solution, and latanoprost. The patient’s central corneal thicknesses were 526 μm OD and 537 μm OS. His IOP in the left eye (OS) was 14 mm Hg unmedicated. His anterior segment examination was otherwise unremarkable OD. On gonioscopy, his angle was grade IV with 3 + pigment in the TM OU. His cup-to-disc ratio was 0.85 OD. His examination OS was unremarkable with a

cup-to-disc ratio of 0.3. He had trace nuclear sclerosis OU. The patient subsequently underwent an ab interno trabeculotomy with a clear 4-0 nylon suture with a marked tip. On the first postoperative day, his vision was 20/25 and his IOP was 10 mm Hg and he had 3 + cells in the anterior chamber with a few blood clots and a microhyphema. He was placed on a topical ocufloxacin ophthalmic solution 4 ×/day, prednisolone acetate 1% 4 ×/day and diclofenac ophthalmic solution twice daily. On the first postoperative week, his vision

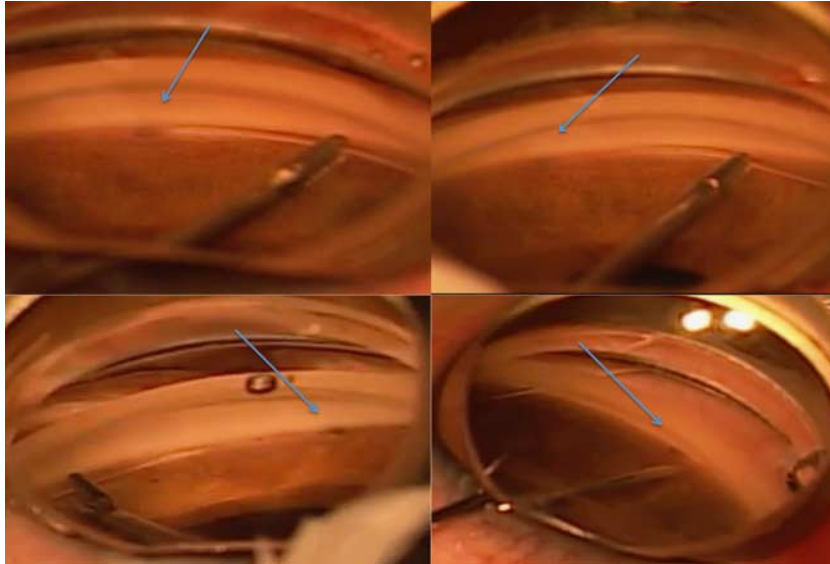


FIGURE 3. Various intraoperative pictures in which a marked thermally blunted tip was used to perform a gonioscopy-assisted transluminal trabeculotomy surgery. The blue arrows demonstrate the location of the marked tip and illustrate how the marked tip aids in identification of the suture within the Schlemm canal.

was 20/20 and his IOP was 16 and the antibiotics were stopped. The blood clots had resolved and his microhyphema was improving. Over the subsequent 2 months, his steroids were slowly tapered and the diclofenac was stopped. On his most recent examination, postoperative month 15, his vision was 20/20, IOP was 14 mm Hg, and he was not on glaucoma medications. His anterior segment examination was otherwise unremarkable.

REFERENCES

1. Harms H, Dannheim R. Epicritical consideration for 300 cases of trabeculotomy 'ab externo'. *Trans Ophthalmol Soc U K.* 1969;89:491–499.
2. Smith R. A new technique for opening the canal of Schlemm. *Br J Ophthalmol.* 1960;44:370–373.
3. Grover DS, Godfrey DG, Smith O, et al. Gonioscopy-assisted transluminal trabeculotomy, ab interno trabeculotomy: technique report and preliminary results. *Ophthalmology.* 2014;121:855–861.
4. Tanihara H, Negi A, Akimoto M, et al. Surgical effects of trabeculotomy ab externo on adult eyes with primary open angle glaucoma and pseudoexfoliation syndrome. *Arch Ophthalmol.* 1993;111:1653–1661.
5. Iwao K, Inatani M, Tanihara H, et al. Success rates of trabeculotomy for steroid-induced glaucoma: a comparative, multicenter, retrospective cohort study. *Am J Ophthalmol.* 2011;151:1047–1056. e1.
6. Chin S, Nitta T, Shinmei Y, et al. Reduction of intraocular pressure using a modified 360-degree suture trabeculotomy technique in primary and secondary open-angle glaucoma: a pilot study. *J Glaucoma.* 2012;21:401–407.
7. Chihara E, Nishida A, Kodo M, et al. Trabeculotomy ab externo: an alternative treatment in adult patients with primary open-angle glaucoma. *Ophthalmic Surg.* 1993;24:735–739.
8. Luntz MH, Livingston DG. Trabeculotomy ab externo and trabeculotomy in congenital and adult onset glaucoma. *Am J Ophthalmol.* 1977;83:174–179.
9. Beck AD, Lynch MG. 360 degrees trabeculotomy for primary congenital glaucoma. *Arch Ophthalmol.* 1995;113:1200–1202.
10. Girkin CA, Marchase N, Cogen MS. Circumferential trabeculotomy with an illuminated microcatheter in congenital glaucomas. *J Glaucoma.* 2012;21:160–163.
11. Sarkisian SR Jr.. An illuminated microcatheter for 360-degree trabeculotomy [corrected] in congenital glaucoma: a retrospective case series. *J AAPOS.* 2010;14:412–416.