

Topical nonsteroidal anti-inflammatory drugs as adjuvant therapy in the prevention of macular edema after cataract surgery

Nicola Cardascia · Carmela Palmisano · Tersa Centoducati · Giovanni Alessio

Received: 15 April 2016 / Accepted: 6 October 2016
© Springer Science+Business Media Dordrecht 2016

Abstract

Purpose The purpose of the study was to assess adjuvant treatment with topical nonsteroidal anti-inflammatory drugs (NSAIDs) (0.9 % bromfenac, 0.1 % nepafenac, 0.5 % indomethacin, or 0.1 % diclofenac) in addition to topical steroidal treatment with 0.1 % dexamethasone and 0.3 % netilmicin for prevention of cystoid macular edema (CME) after uneventful small incision cataract extraction with foldable intraocular lens (IOL) implantation.

Setting Institute of Ophthalmology, Department of Scienze Mediche di Base, Neuroscienze ed Organi di Senso, Aldo Moro University, Policlinico Consorziiale di Bari, Bari, Italy.

Design A retrospective 6-month single center study.

Methods Patients were divided into groups according to treatment with topical drugs for 2 weeks, after phacoemulsification with foldable IOL implantation. CME incidence was evaluated by assessing retinal foveal thickness changes using spectral domain optical coherence tomography. All patients were treated

with a fixed combination of dexamethasone and netilmicin, and some patients were additionally treated with NSAIDs (bromfenac, nepafenac, indomethacin, or diclofenac).

Results Fourteen patients were treated with bromfenac, 15 with nepafenac, 12 with indomethacin, and 14 with diclofenac; ten patients were treated with dexamethasone and netilmicin alone. At the end of the follow-up, macular thickness, evaluated at 1-week post-surgery, was reduced only in the group treated with nepafenac (-1.3% , $p = 0.048$), was increased in the group treated with dexamethasone and netilmicin alone ($+4.3\%$, $p = 0.04$), and did not change in the groups treated with bromfenac (-1.1% , $p = 0.3$), indomethacin ($+0.1\%$, $p = 0.19$), or diclofenac ($+1.2\%$, $p = 0.74$). There were no side effects in any group.

Conclusions Topical treatment with nepafenac, bromfenac, and indomethacin enhanced the efficacy of steroids to reduce postoperative macular edema. Diclofenac did not improve steroids efficacy.

Keywords Cataract · Surgery · NSAID · OCT · Macular edema

N. Cardascia · C. Palmisano · T. Centoducati · G. Alessio

Dipartimento di Scienze Mediche di Base, Neuroscienze ed Organi di Senso. Sezione di Oftalmologia, Università degli Studi di Bari Aldo Moro, Bari, Italy

N. Cardascia (✉)
RUO Oftalmologia, Policlinico Consorziiale di Bari, p.zza G. Cesare, 11, 70124 Bari, Italy
e-mail: cardascia@hotmail.com

Introduction

Cataract surgery with foldable lens implantation is the most challenging ophthalmic surgery in developed

countries. Quick recovery of visual acuity and uneventful surgery can be achieved by an effective technical approach and appropriate therapy. With an incidence of 0.1–9 %, macular edema is one of the most important complications of cataract surgery. It is the main cause of postoperative visual impairment, even in patients without risk factors and in cases of uneventful surgery [1]. [2] Postoperative macular swelling is induced by prostaglandins [3], which are products of arachidonic acid conversion via COX-1 and COX-2 pathways. In the eye, increased production of COX-2 occurs in response to exposure to a noxious surgical stimulus [4]. Nonsteroidal anti-inflammatory drugs (NSAIDs) inhibit prostaglandin biosynthesis and prevent macular edema [5]. Although the COX-2 pathway is the most important mechanism involved in ocular surgical inflammation, topical nonsteroidal inhibitors of both COX-1 and COX-2 can be used postoperatively to decrease inflammation. In this study, we characterized adjuvant therapy with topical 0.5 % indomethacin, 0.1 % diclofenac, 0.9 % bromfenac, and 0.1 % nepafenac in the prevention of postoperative macular edema.

Patients and methods

This retrospective 6-month single center study was approved by the Independent Italian Ethical Committee, in accordance with the tenets of the Declaration of Helsinki, and was conducted at the Department of Ophthalmology of Bari University, Bari, Italy. We included all patients aged >50 years who had an uneventful 2.75-mm clear corneal incision and phacoemulsification cataract extraction with intraocular lens (IOL) implantation between January and June 2015. Exclusion criteria included diabetes, severe liver disorder, kidney or heart disorder, systemic chronic autoimmune disease, allergy or drug sensitivity, a history of macular edema (age-related maculopathy, diabetic retinopathy, or retinal vascular disorder), vitreoretinal interface disease, previous ophthalmic surgery, chronic or recurrent ocular inflammation, ocular digenesis (congenital cataract, aniridia, or iris atrophy), corneal disorder, or glaucoma or pseudoexfoliation.

Of 2234 patients scheduled for cataract surgery, 65 Caucasian patients (36 women and 29 men; mean age, 70.6 ± 7.1 years; range 52–86 years) met the

inclusion criteria and were enrolled in the study. All patients received topical therapy comprising a fixed combination of dexamethasone and netilmicin. Patients were divided into groups when they were scheduled for surgery, based on additional treatment with topical NSAIDs (t-NSAIDs). There were a total of five groups: patients treated with 0.9 % bromfenac, 0.1 % nepafenac, 0.5 % indomethacin, and 0.1 % diclofenac; and a control group who received only dexamethasone and netilmicin treatment, without any t-NSAID. The t-NSAIDs were administered via one eye drop three times a day, starting 2 days before surgery and ending 2 weeks after surgery. Baseline characteristics of the treatment groups were comparable. All patients underwent a sutureless 2.75-mm clear cornea incision, continuous curvilinear capsulorhexis, lens phacoemulsification using the divide and conquer technique, and implantation of an acrylic foldable IOL (IOL Prime FIL 611; Soleko, IOL Division, Rome, Italy). The mean phacoemulsification time was similar among the groups ($p > 0.05$; Table 1). All surgical procedures used a 1 % hyaluronic cohesive viscoelastic solution (Biolon; SIFI SpA, Aci Sant'Antonio (CT), Italy). The incidence of macular edema was evaluated by determining retinal macular thickness using spectral domain optical coherence tomography (RTVue; Optovue, Fremont, CA, USA) at baseline and postoperatively at 7, 14, and 30 days. The MM6 macular thickness protocol was used, consisting of six radial line scans centered on the fovea with a retinal thickness tabular output. The central retinal thickness was defined as the distance between the inner limiting membrane of the retina and the inner border of the choriocapillaris measured within an inner 1-mm area of the MM6 circular scan of the posterior pole. Cystoid macular edema (CME) was clinically determined using angiography and fundus fluorescence angiography (FFA), which was the gold standard for evaluating macular swelling before tomography became available. Optical coherence tomography (OCT) is a noncontact and noninvasive ophthalmic imaging technique that provides more detailed tomographic images than FFA in cases of mild macular edema [6]. OCT is therefore the best method to obtain quantitative and qualitative data for postoperative macular edema. The student's *t* test, repeated measures analysis of variance, and Fisher's test were used for statistical analyses. A value of $p < 0.05$ was considered statistically significant.

Table 1 Demographic and ocular characteristics of selected groups of patients based on their topical treatment with nonsteroidal anti-inflammatory drugs

Groups	Patients	Eyes	Male/female	Age (years)	Axial length (mm)	Phaco time (sec)
Bromfenac	14	21	8/6	70.5 ± 6.4	23.1 ± 1.3	35.6 ± 18.3
Nepafenac	15	24	6/9	69.5 ± 6.5	23.7 ± 2.3	34.9 ± 17.5
Indomethacin	12	21	6/6	72.3 ± 7.9	23.3 ± 1.1	36.1 ± 15.2
Diclofenac	14	26	5/9	74.7 ± 6.9	23.2 ± 0.8	35.1 ± 13.9
Dexamethasone	10	19	4/6	65.4 ± 7.1	23.3 ± 0.9	36.2 ± 16.1

Results

Fourteen patients were treated with bromfenac, 15 with nepafenac, 12 with indomethacin, and 14 with diclofenac, all in combination with dexamethasone and netilmicin; 10 patients were treated with dexamethasone and netilmicin alone. Baseline demographic and ophthalmic data are listed in Table 1. One week after surgery, all eyes had significant tomographic macular thickening (nepafenac and diclofenac, $p = 0.0002$; bromfenac, indomethacin, and dexamethasone and netilmicin alone, $p < 0.0001$). One month after surgery, macular thickness was reduced only in the group treated with nepafenac (-1.3% , $p = 0.048$), and was increased in the group treated with dexamethasone and netilmicin alone ($+4.3\%$, $p = 0.04$), but did not change in the groups treated with bromfenac (-1.1% , $p = 0.3$), indomethacin ($+0.1\%$, $p = 0.19$), or diclofenac ($+1.2\%$, $p = 0.74$) (Fig. 1). The efficacy of each treatment was determined by comparing the changes in macular thickness 1 week after surgery. The best efficacy was found in the groups treated with nepafenac ($OR = 8.9$, $p = 0.004$) and indomethacin ($OR = 7.1$, $p = 0.01$). Bromfenac treatment showed moderate efficacy ($OR = 4$, $p = 0.09$), but diclofenac treatment had no effect on macular edema ($OR = 0.91$, $p = 0.1$) (Fig. 2). There were no side effects in any of the groups.

Discussion

The rationale for the treatment of macular edema induced by cataract surgery is based on an understanding of the etiology and inhibition of pathophysiological mechanisms. The main factor initiating macular edema is the release of inflammatory

mediators responsible for the breakdown of the blood–retinal barrier. NSAIDs inhibit cyclooxygenase and prostaglandin production, modulate fluid movement, and reduce the incidence of macular swelling [7]. The ability of t-NSAIDs to penetrate ocular tissues, including the retina, is important in the treatment and prevention of macular edema. Baklayan et al. reported that a highly lipophilic ophthalmic solution of bromfenac rapidly penetrated ocular tissues, resulting in both rapidly achieved and sustained drug levels in all relevant ocular tissues, including the retina, for >24 h following a single topical administration [8]. Zaczek et al. reported that a combination of topical nepafenac and steroid treatment reduced subclinical macular swelling and inflammation, as well as subjective complaints after cataract surgery [9]. Maca et al. reported that a preservative-free formulation of topical diclofenac prevented postoperative macular edema, with significant subjective and objective tolerability, after cataract extraction [10]. Yavas reported that preoperative and postoperative treatment with indomethacin prevented CME induced by cataract surgery [11]. Steroidal anti-inflammatory drugs (SAIDs) are also well known for their effects on inflammation and cellular proliferation. Corticosteroids inhibit the arachidonic acid cascade, decrease the permeability of the blood–retinal barrier, and modulate macular swelling [12]. Three additional studies, which could not be directly compared, reported that t-NSAIDs in combination with topical steroids had a therapeutic effect on macular edema induced by cataract surgery [13]. Macular edema can lead to permanent structural damage of the retinal outer nuclear layers, resulting in irreversible visual loss. A minimally traumatic and quick cataract surgery is the best way to prevent macular edema. Topical NSAIDs can be used as adjuvants to intraoperatively stabilize pupillary

Fig. 1 Mean macular thickness changes assessed by spectral domain optical coherence tomography (Optovue MM6) during follow-up (days). The maximum postoperative change was at 7 days, followed by regression after 14 days of therapy with bromfenac, nepafenac, or indomethacin

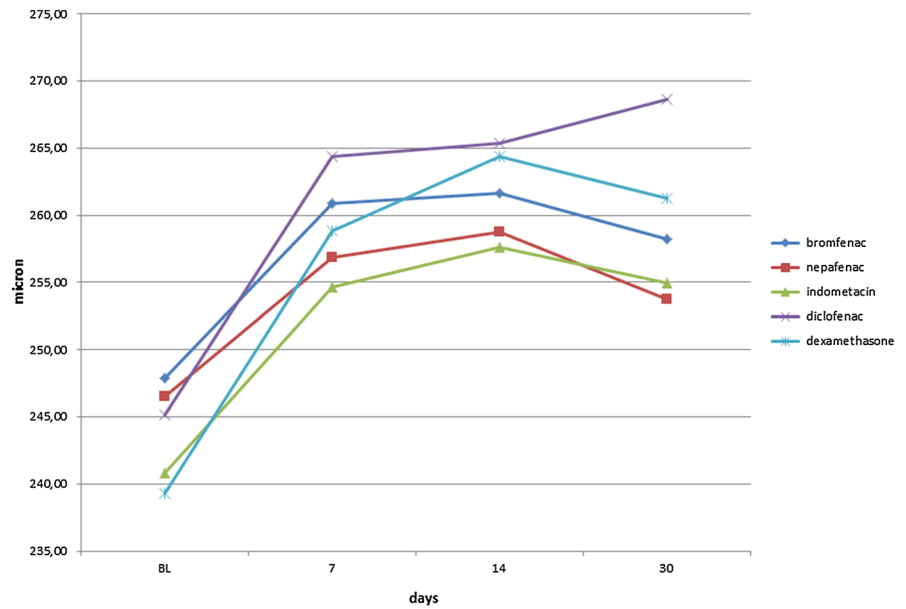
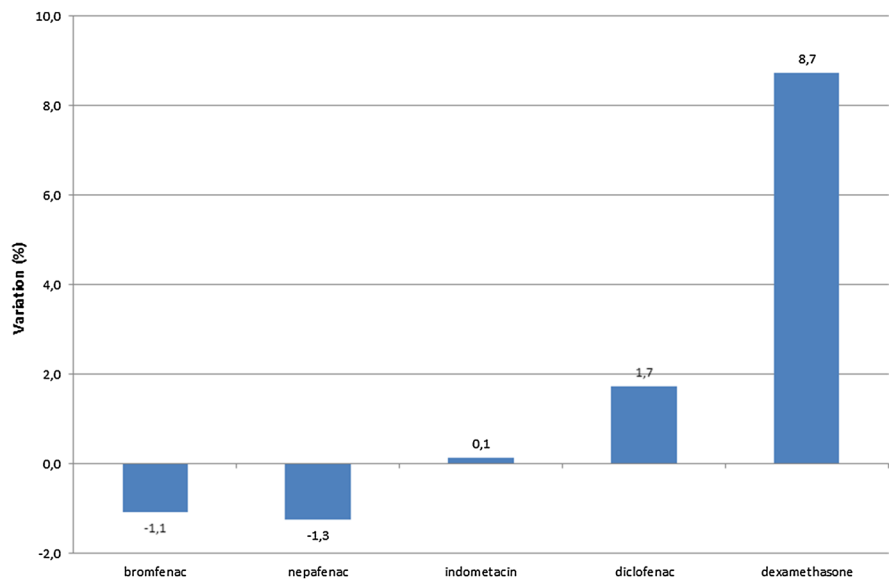


Fig. 2 Spectral domain optical coherence tomography evaluation of mean macular thickness change between 7 and 30 days post-surgery. There was a change in macular edema after treatment with bromfenac or nepafenac, but not with indomethacin or diclofenac



dilation, and postoperatively reduce inflammation, pain, and the occurrence of macular edema [14]. Our results suggest that macular edema usually peaks approximately 1 week after surgery and regresses thereafter. Previous studies have reported that bromfenac, nepafenac, and indomethacin, together with t-SAIDs, significantly reduced retinal thickening 1 month after surgery. These results demonstrate the prophylactic effects of t-NSAIDs on postoperative macular edema [15]. The results of the present study confirm that topical treatment with bromfenac or

nepafenac enhanced the efficacy of steroids to reduce postoperative macular edema; indomethacin had a significant effect on macular edema, but diclofenac showed no efficacy.

References

- Miyake K, Ota I, Miyake G, Numaga J (2011) Nepafenac 0.1% versus fluorometholone 0.1% for preventing cystoid macular edema after cataract surgery. *J Cataract Refract Surg* 37(9):1581–1588

2. Mathys KC, Cohen KL (2010) Impact of nepafenac 0.1% on macular thickness and postoperative visual acuity after cataract surgery in patients at low risk for cystoid macular edema. *Eye (Lond)* 24(1):90–96
3. Miyake K, Ibaraki N (2002) Prostaglandins and cystoid macular edema. *Surv Ophthalmol* 47(suppl 1):S203–S218
4. Oka T, Shearer TR, Azuma M (2004) Involvement of cyclooxygenase-2 in rat models of conjunctivitis. *Curr Eye Res* 29:27–34
5. Sivaprasad S, Bunce C, Wormald R (2005) Non-steroidal anti-inflammatory agents for cystoid macular oedema following cataract surgery: a systematic review. *Br J Ophthalmol* 89:1420–1422
6. Almeida DR, Johnson D, Hollands H, Smallman D, Baxter S, Eng KT et al (2008) Effect of prophylactic nonsteroidal antiinflammatory drugs on cystoid macular edema assessed using optical coherence tomography quantification of total macular volume after cataract surgery. *J Cataract Refract Surg* 34:64–69
7. Yavas GF, Oztürk F, Küsbeci T (2007) Preoperative topical indomethacin to prevent pseudophakic cystoid macular edema. *J Cataract Refract Surg* 33:804–807
8. Baklayan GA, Patterson HM, Song CK, Gow JA, McNamara TR (2008) 24-Hour evaluation of the ocular distribution of ¹⁴C-labeled bromfenac following topical instillation into the eyes of New Zealand white rabbits. *J Ocul Pharmacol Ther* 24(4):392–398
9. Zaczek A, Artzen D, Laurell CG, Stenevi U, Montan P (2014) Nepafenac 0.1% plus dexamethasone 0.1% versus dexamethasone alone: effect on macular swelling after cataract surgery. *J Cataract Refract Surg* 40(9):1498–1505
10. Maca SM, Amon M, Findl O, Kahraman G, Barisani-Asenbauer T (2010) Efficacy and tolerability of preservative-free and preserved diclofenac and preserved ketorolac eyedrops after cataract surgery. *Am J Ophthalmol* 149(5):777–784
11. Yavas GF, Oztürk F, Küsbeci T (2007) Preoperative topical indomethacin to prevent pseudophakic cystoid macular edema. *J Cataract Refract Surg* 33(5):804–807
12. McColgin AZ, Heier JS (2000) Control of intraocular inflammation associated with cataract surgery. *Curr Opin Ophthalmol* 11(1):3–6
13. Sivaprasad S, Bunce C, Patel N (2012) Non-steroidal anti-inflammatory agents for treating cystoid macular oedema following cataract surgery. *Cochrane Database Syst Rev* 15(2):CD004239
14. Kim SJ, Flach AJ, Jampol LM (2010) Nonsteroidal antiinflammatory drugs in ophthalmology. *Surv Ophthalmol* 55(2):108–133
15. Kessel L, Tendal B, Jørgensen KJ, Erngaard D, Flesner P, Andresen JL, Hjortdal J (2014) Post-cataract prevention of inflammation and macular edema by steroid and nonsteroidal anti-inflammatory eye drops: a systematic review. *Ophthalmology* 121(10):1915–1924